



## Adie's pupil during migraine attack: case report and review of literature

Abbas TAFAKHORI, Vajiheh AGHAMOLLAII, Amirhossein MODABBERNIA, Hossein POURMAHMOODIAN

Iranian Center for Neurological Research, Department of Neurology, Imam Khomeini Hospital, Tehran University of Medical Sciences, Tehran, Iran

### Abstract

*Association of migraine and tonic pupil has been reported very rarely. We reported a young female with symptoms of migraine who developed a mydriatic pupil in one of her attacks. The pupil was unresponsive to light with little response to near reflex. In 0.125% pilocarpine test affected pupil responded significantly and tonic pupil was diagnosed. The patient's problem became severe after a one-year follow up. We discussed possible mechanisms and reviewed previous cases with the same diagnosis. Evidences show that this association may be caused by infarction of parasympathetic fibers secondary to prolonged vasospasm which sometimes occurs in migraine.*

**Key words:** Adie's pupil; tonic pupil; migraine.

### Introduction

Adie's (tonic) pupil is defined as a mydriatic pupil, which is unresponsive to light and is moderately responsive to accommodation. The damage to postganglionic parasympathetic fibers may cause this syndrome. Diagnosis is established with rapid miotic response of affected pupil to 0.125% pilocarpine drop (1). Diseases such as Giant cell arteritis, Sjogren's syndrome, malignancies, paraneoplastic anti-Hu antibody syndrome and infections have been reported to be associated with tonic pupil (2-4). There are few reports on occurrence of Adie's pupil during a migraine attack (1, 5-7). Here we described a patient with a history of migraine who develops Adie's pupil during one of her attacks.

### Case report

A 27-year-old female presented with the alteration of the size of her pupil. She also noted a concomitant throbbing headache mostly behind her left eye as well as dysesthesia of the face on the same side which was accompanied by nausea, photophobia, pallor and dry mouth. The headache was present for

years with a frequency of every two days. The episodes took about 24 hours to improve without any treatment. The change in the size of her pupil had occurred during one of the attacks and had not been subsided after relief of the headache. She also complained of blurred vision mainly at the time of reading. Her pain was relieved with manual pressure on the temporal area and also vomiting. Facial dysesthesia occurred during the headache episode and was subsided with headache improvement. No medication overuse was noted. A positive family history was present for Migraine. Drug, habit and past histories were unremarkable other than a history of similar headaches for several years. Her general physical examination was unremarkable. In the neurological examination left pupil was mydriatic (of about 5 mm) and round in shape and the right pupil was midsize (3.5 mm). There was no response to light in the left pupil. No abnormalities in the eye movement as well as fundal examination were detected. In the examination of near reflex, the size of left pupil reduced slowly but not completely. Deep tendon reflexes were 2+ in all extremities. Perimetry and examination of visual acuity were normal. Other neurological examinations revealed no abnormality. Cell count, sedimentation rate, and routine blood chemistries, were normal and anti-Ro, anti-La, anti RNP and VDRL were negative. Brain MRI and MRA showed no abnormality. In the 0.125% pilocarpine test there was a significant response in the left pupil with remarkable reduction of its size to about 3 mm after about 20 minutes (Fig. 1). A diagnosis of tonic pupil and migraine without aura (using IHC criteria) was established. Amitriptyline 25 mg every night and propranolol 20 mg twice daily was prescribed and the patient's headache improved significantly. The pupil problem was followed for one year without treatment. The problem with near vision became more severe over time, and in addition, the size of the left pupil increased to about 7 mm. Pilocarpine test together with MRI and MRA

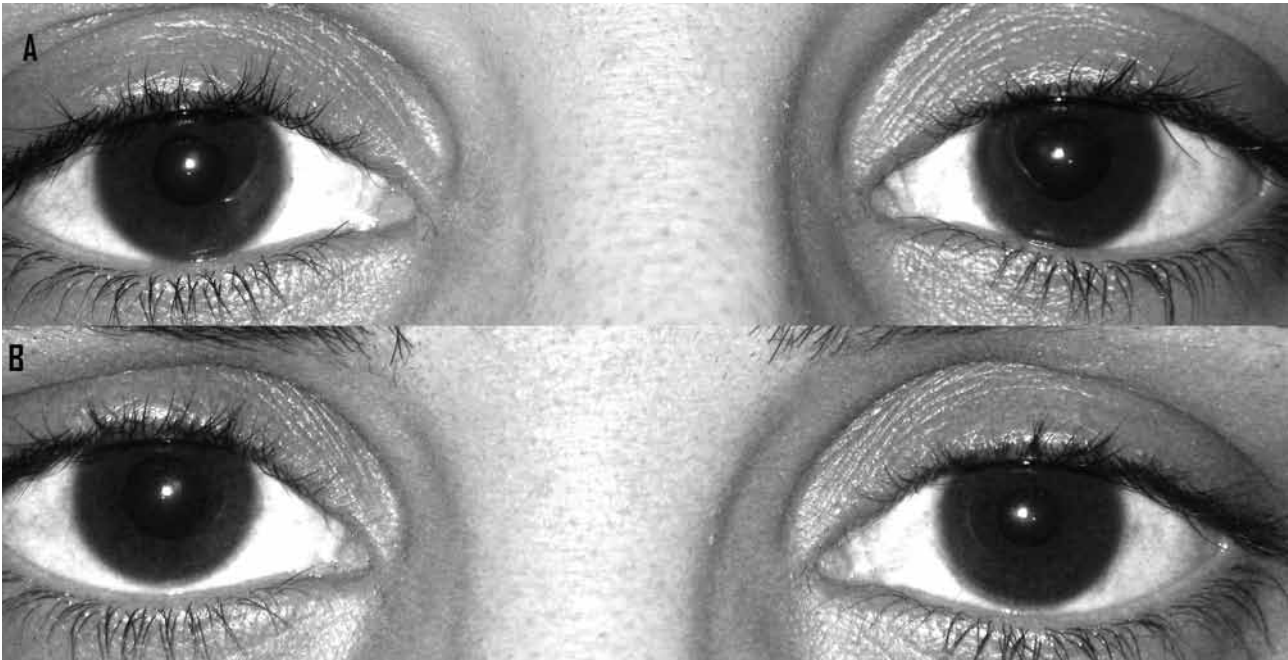


FIG. 1. — Panel A shows dilated left pupil which is unresponsive to light. Panel B shows miosis of left pupil about ten minutes after administration of 0.125% pilocarpine.

were performed and the diagnosis of tonic pupil was confirmed again. Deep tendon reflexes were still 2+. 0.125% pilocarpine drop was prescribed twice daily for the eye problem and the need of the patient to pilocarpine halved within one week of the initiation of the drop.

### Discussion

Massey in 1981 noted the possible link between migraine and tonic pupil. He studied 22 patients with tonic pupil and identified the personal and family history of migraine in eight and nine of them respectively (8). However, the simultaneous occurrence of migraine and tonic pupil was not reported until 1995, when Purvin reported the first case of co-occurrence of migraine and Adie's pupil. Using Pubmed and Scopus engines and search terms of "tonic pupil" or "Adie's pupil" AND "migraine" or "headache" we only identified four previous cases of concomitant migraine and tonic pupil (6). There was also an additional case in which association of hemicrania and tonic pupil was reported (9). A summary of the characteristics of these patients were extracted and presented in table 1.

The underlying mechanism of the link between tonic pupil and migraine remains to be established. In Adie's pupil, denervation of postganglionic parasympathetic fibers occurs, leading to super-

sensitive response to cholinergic agonists. Sometimes it may be part of a syndrome, the Holmes Adie's syndrome in which, tonic pupil is associated with absent or reduced deep tendon reflexes (10). Any damage to postganglionic parasympathetic fibers can lead to manifestations of Adie's pupil. These can be inflammation, autoantibodies, dysautonomia (as in Harlequin and Ross syndrome) or ischemia (10). Although pallor and dry mouth in our patient make the diagnosis of dysautonomia a possibility, ischemic damage may be a more suitable diagnosis. Ischemia occurs in migraine, particularly in prolonged attacks and it is possible that, a prolonged vasospasm occurred in our patient and caused infarction of the postganglionic fibers leading to permanent dysfunction of the left pupil (6).

Although we and several others, proposed ischemia as the possible cause, more studies are warranted in this area and with regard to its rarity, every report of this association should be taken into account to improve our knowledge and experience.

### REFERENCES

1. Iannetti P. *et al.* Residual and persistent Adie's pupil after pediatric ophthalmoplegic migraine. *Pediatr Neurol.* 2009;41(3):204-6.
2. Muller NG, Prass K, Zschenderlein R. Anti-Hu antibodies, sensory neuropathy, and Holmes-Adie syndrome in a patient with seminoma. *Neurology.* 2005;64(1):164-5.

Table 1  
Characteristics of reported patients with concomitant migraine and Adie's pupil

Gender/age (reference number)	Characteristics of headache	Past history	Pupillary involvement	Migraine type	Associated findings	outcome
46/female (6)	Bifrontal, throbbing, with photophobia, relieved with sleep	Recurrent headaches for 20 years Obesity, arthritis	Unilateral	Migraine with visual aura		Tonic pupil persisted after occurring for the second time
27/female (5)	Left orbito-frontal headache persisted for two months, no photosensitivity	Recurrent headache for 8 years, hypertension, anxiety disorders	Bilateral (first left pupil, after 6 months the right pupil)	Status migrainosus	Dispersed median and ulnar sensory potentials (Adie's syndrome)	Twenty two months after onset of eye symptoms, the left pupil normalized but the right one remained tonic
18/female (7)	An unusually severe episode compared with previous episodes	Recurrent headache since childhood	Bilateral	Migraine without aura		Improved within one week
9/female (1)	Severe headache, phonophobia, photophobia,	Two year history of migraine, 6 months history of ophthalmoplegic attacks	Unilateral	Migraine with aura/ added ophthalmoplegic migraine	Vomiting vertigo, convergent diplopia	Ophthalmoplegia subsided. Adie's pupil remained unchanged after a two-year follow up
27/female (present case)	Severe throbbing headache in orbitofrontal area, photophobia, relieved with pressure, vomiting	History of migraine since childhood	Unilateral	Migraine without aura	Vomiting, dysesthesia of the face, dry mouth pallor	The size of pupil increased and the near vision weakened over time
23/female (9)	Severe, unilateral, non-throbbing, fronto orbital	Recent onset of hemicrania	Unilateral	Hemicrania	Nasal congestion, rhinorrhea, conjunctival hyperemia, lacrimation	N/A

3. Bachmeyer C. *et al.* Adie syndrome as the initial sign of primary Sjogren syndrome. *Am J Ophthalmol.* 1997;123(5):691-2.
4. Foroozan R. *et al.* Tonic pupils from giant cell arteritis. *Br J Ophthalmol.* 2003;87(4):510-2.
5. Jacome DE. Status Migrainosus and Adie's syndrome. *Headache.* 2002;42(8):793-5.
6. Purvin VA. Adie's tonic pupil secondary to migraine. *J Neuroophthalmol.* 1995;15(1):43-4.
7. Drouet A. *et al.* [Adie's tonic pupil and migraine: a chance association?]. *J Fr Ophtalmol.* 2008;31(2):e5.
8. Massey EW. Pupillary dysautonomia and migraine: is Adie's pupil caused by migraine? *Headache.* 1981;21(4):143-6.
9. Rodrigues CL. *et al.* Holmes-Adie pupil in a patient with hemicrania: a spectrum of a multifocal autonomic dysfunction? *Arq Neuropsiquiatr.* 2008; 66(2B):423-4.
10. Shin RK. *et al.* Ross syndrome plus: beyond horner, Holmes-Adie, and harlequin. *Neurology.* 2000; 55(12):1841-6.

Abbas Tafakhori, M.D.,  
Vajiheh Aghamollaii, M.D.,  
Amirhossein Modabbernia, M.D.,  
Hossein Pourmahmoodian\*, M.D.,  
\*Corresponding author:  
Iranian Center for Neurological Research,  
Department of Neurology,  
Imam Khomeini Hospital,  
Tehran University of Medical Sciences,  
Tehran, Iran  
Amirh899@gmail.com